



**PATIENT**  
Winslow Randall

**PRESENTING CLINICAL SIGNS**

History: New grade II-III/VI murmur. Chronic eosinophilic granuloma patient who has been treated with depo-medrol and diet change (RC Hypo diet) for several years. Most recently on Cyclosporine to decrease frequency of injections. (100mg/ml, 0.3ml SID). ProBNP: 478.

**SPECIES**  
Feline

**ECHOCARDIOGRAM FINDINGS**

2D, m-mode, color flow and Doppler imaging is available.

**BREED**  
DSH

**Left ventricle:** The LV diameter is mildly decreased with adequate myocardial function. The LV wall thicknesses are moderately increased, with regions of irregularity. There is a diffusely hyperechoic endocardium consistent with fibrosis. The papillary muscles are mildly hypertrophied and hyperechoic. The endocardium appears remodeled.

**SEX**

Male Neutered

**Left atrium:** The left atrium is mildly dilated. No smoke or thrombi seen.

**AGE**

4 years

**Mitral valve:** The anterior leaflet of the mitral valve appears largely normal. Systolic anterior motion is seen on 2D imaging. Mild to moderate eccentric MR.

**Aortic valve/Aorta:** The aortic valve is normal in morphology and mobility. Moderately increased aortic outflow velocity with a dynamic profile. No aortic insufficiency.

**WEIGHT**  
13.75lbs

**Right ventricle:** Normal right ventricular diameter and morphology indicating no overt evidence of pulmonary arterial hypertension.

**Right atrium:** The right atrium is normal in dimension.

**Tricuspid valve:** The tricuspid valve appears normal with trace tricuspid regurgitation.

**Pulmonary valve/Pulmonary artery:** The pulmonic valve is normal in morphology and mobility. No pulmonic insufficiency. Normal RVOT velocity.

**Pericardium/other:** No pericardial or pleural effusion noted. No obvious cardiac masses.

**Heart rhythm:** ECG reveals a sinus rhythm with an average HR of 160bpm.

**INTERPRETED BY**

Maggie Machen  
Lamy, DVM  
DACVIM (Cardiology)

**2-Dimensional Measurements**

Ao diam (cm)	1.2
LA diam (cm)	1.4
LA:Ao (Swe)	1.2
IVS thickness (cm)	0.73
LVID diastole (cm)	1.6
PW thickness (cm)	0.84
LVID systole (cm)	0.73
FS (%)	57

**Doppler Measurements**

PV Vmax (m/s)	1.0
AoV Vmax (m/s)	4.2
MR Vmax (m/s)	NA
TR Vmax (m/s)	NA
TR PG (mmHg)	NA

**IMAGING PERFORMED BY**

Pamela Harrigan,  
RDMS

**HOSPITAL NAME**

Barnstable Veterinary  
Hospital

**INTERPRETATION OF THE FINDINGS**

The diagnosis and cause of the murmur is hypertrophic obstructive cardiomyopathy. This indicates some degree of LV thickening (moderate in this case) with a dynamic LVOT obstruction (SAM). There is mild left atrial dilation, indicating the risk for progression to spontaneous CHF and/or a thrombotic event is currently low. No additional issues are identified. Hyperthyroidism and hypertension should be ruled out as contributing factors in this normotensive cat.

**REFERRING VET**

Dr. McCartney

**INVOICE**  
26923

While no medications have been shown to definitively alter long term outcome at this stage of disease, atenolol is often initiated to decrease the outflow obstruction. If there is difficulty medicating at home, an alternative approach would be closely monitoring for progression in the next 6 months; however, given degree of the LV hypertrophy and tachycardia I would recommend initiation at this time. Prognosis is guarded due to the highly variable nature of feline subclinical cardiomyopathy.

**DATE**  
10/17/22



**PATIENT**

Winslow Randall

**SPECIES**

Feline

**BREED**

DSH

**SEX**

Male Neutered

**AGE**

4 years

**WEIGHT**

13.75lbs

**INTERPRETED BY**

Maggie Machen  
 Lamy, DVM  
 DACVIM (Cardiology)

**IMAGING PERFORMED BY**

Pamela Harrigan,  
 RDMS

**HOSPITAL NAME**

Barnstable Veterinary  
 Hospital

**REFERRING VET**

Dr. McCartney

**INVOICE**

26923

**DATE**

10/17/22

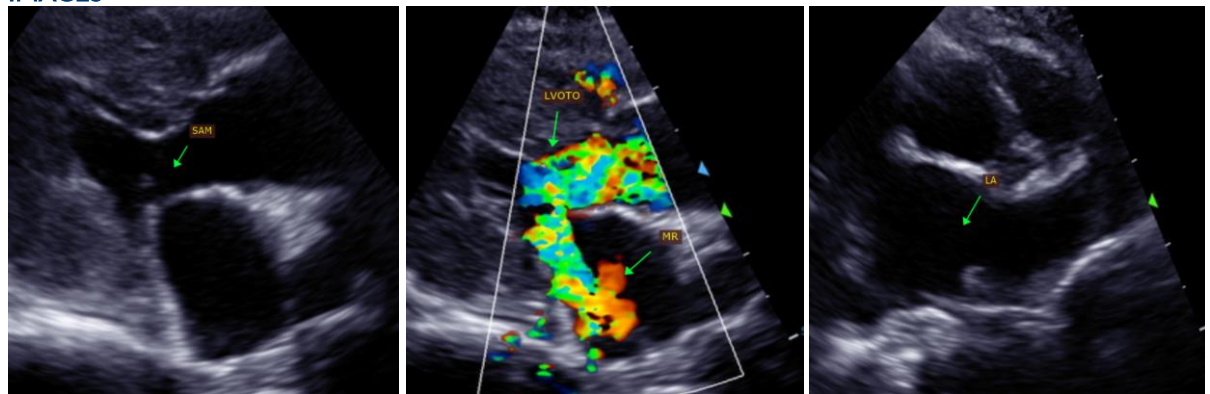
**RECOMMENDATIONS**

- If able, administer titrating dose of atenolol: 25mg tablets; Give ¼ tab once daily. Recheck heart rate in 1-2 weeks with target stressed rate of 140-160bpm 12-24 hours post-administration. Increase as needed until target reached.
- Screening BP/T4 every 6 months.
- Anesthetic risk is considered mildly elevated, however judicious IV fluid rates are advised to avoid fluid overload. Additionally, drugs that stimulate heart rate should be avoided unless clinically necessary (glycopyrrolate, atropine).
- Monitor for any clinical evidence of cardiac compromise, including respiratory changes and/or signs of a blood clot event (paralysis, neurologic changes, etc.).

**PLAN**

- Recommend recheck echocardiogram in 6 months to assess rate of progression, sooner if any issues arise in the interim.

**IMAGES**



The information and recommendations provided are based on the images presented by the referring veterinarian. No evaluation can be communicated regarding pathology that was not visible in the image/video clips provided.

Thank you for this referral. This report was generated using transcription software, and minor dictation errors may be present. If the clinical or image interpretation does not parallel your findings or if I can be of any further assistance, please contact me.

**Maggie Machen Lamy, DVM**  
 Diplomate of the American College of Veterinary Internal Medicine (Cardiology)  
 info@sonopath.com